

## Idiopathic vs acquired pedophilic behavior: a critical analysis

### Comportamento pedofilico idiopatico e acquisito: un'analisi critica

*Cristina Scarpazza • Andrea Sigfrido Camperio Ciani • Stefano Ferracuti*

#### **Abstract**

Acquired pedophilia is a rare but underestimated condition. Acquired pedophilic behavior refers to the insurgence of pedophilic tendencies as result of a neurological disorder, that cause a fracture between behaviors observed prior and after the brain insult. Acquired pedophilia widely differs from idiopathic pedophilia. The current review of the literature summarizes the actual knowledge on the differences between acquired and idiopathic pedophilia in the following aspect: etiology, neural correlates, modus operandi, possible treatments and legal consequences. We conclude underlying that appreciating the possibility of an acquired origin of pedophilic behavior is of utmost importance, for clinical and forensic reasons. An interdisciplinary approach must be acted in all cases under observation.

**Keywords:** acquired pedophilic behavior; behavioral fracture; modus operandi; interdisciplinary approach; neurological insult

#### **Riassunto**

La pedofilia acquisita è una condizione rara ma sottostimata. Per comportamento pedofilico acquisito si intende l'insorgenza di tendenze pedofiliche come conseguenza di un disturbo neurologico che causa una frattura comportamentale tra i comportamenti manifestati dal soggetto prima e dopo l'insorgenza del danno cerebrale. La pedofilia acquisita differisce dalla pedofilia idiopatica. Questa revisione della letteratura riassume le conoscenze attuali sulle differenze tra pedofilia acquisita e idiopatica nei seguenti aspetti: eziologia, correlati neurali, modus operandi, possibili trattamenti e conseguenze legali. Il lavoro si conclude sottolineando che essere consapevoli della possibile origine neurologica della pedofilia è estremamente importante, sia dal punto di vista clinico e forense. Un approccio interdisciplinare dovrebbe essere adottato in tutti i casi sotto osservazione.

**Parole chiave:** comportamento pedofilico acquisito; frattura comportamentale; modus operandi; approccio interdisciplinare; insulto neurologico

---

**Correspondence** Cristina Scarpazza, [cristina.scarpazza@gmail.com](mailto:cristina.scarpazza@gmail.com), [cristina.scarpazza@unipd.it](mailto:cristina.scarpazza@unipd.it)

Cristina SCARPAZZA, Department of General Psychology, University of Padova  
Andrea Sigfrido CAMPERIO CIANI, Department of Philosophy, Sociology, Education and Applied Psychology, University of Padova  
Stefano FERRACUTI, Department on Neuroscience, Sapienza University of Rome

## 1. Introduction

On June 2016, a 30 years-old man (R.H.) was given 22 life sentences for serious sexual assault against a minimum of 71 children. During the hearings, R.H. revealed some of the stratagems he employed to procure victims, such as taking children out on day trip from foster homes and escorting them home from their own birthday party. He produced child pornography and he shared photos of his crimes with other pedophiles. He was proven to be fully aware of his behaviors, that were carried out in a logical, reasoned and predatory way. He said that “impoverished kids are definitely much easier to seduce than middle-class kids”, revealing his thoughtful selection of his victims. His neurological and neuropsychological examinations were normal. R.H. is one of the many developmental pedophiles that mostly come to public attention.

In 1862 a 78 years-old man (H.) without previous criminal record was charged with child abuse (von Kfrafft-Ebing, 1897). He sexually assaulted a 13 years-old child while he was playing with lizards. The man touched the child penis saying: “this is a beautiful lizard”. After his arrest, doctors realized that, while his body was healthy, his cognitive functions were severely impaired: his language was tangential, his memory was severely impaired, he was not able to understand basic legal rights, he demonstrated not to appreciate the moral and legal disvalue of the behaviors he was charged with. The man was then diagnosed with dementia and was held not responsible for the criminal offenses he was charged with. To our knowledge, this is the first documented case of acquired pedophilia.

Although idiopathic pedophilia is widely known and described in the literature (e.g. Hall & Hall, 2007; Seto et al. 2009; Tenbergen et al. 2015 for reviews), little is still known regarding acquired pedophilia. The term acquired pedophilia refers to the insurgence of pedophilic interest and behaviors in previously heterosexual men (it has never been described in women so far) after a brain insult. Indeed, despite it is widely known that neurological disorders are commonly associated with psychiatric symptoms, it is less evident and clear that a number of neurological disorders can show a predominant behavioral and sometimes bizarre presentation and for this reason can sometimes be mistakenly diagnosed as psychiatric (Butler & Zeman, 2005; Keshavan & Kaneko, 2013). This is the case of acquired pedophilic behavior. Acquired pedophilia is still under-investigated in literature probably because it is a rare phenomenon. However, to have a good knowledge of the differences between idiopathic and acquired pedophilia is of utmost importance both from the medical and from the forensic point of view. Acquired pedophilic behavior differs from idiopathic pedophilic disorder in many aspects: eti-

ology, underlying neural correlates, *modus operandi*, possible therapies and legal consequences. This short review is structured to clarify the differences between these two different forms of pedophilic behavior. The importance of this review lies in the moral, medical and legal consequences of a mis-diagnosis: forensic consultants should be appropriately trained to identify possible acquired pedophilia cases in order to select the most effective therapy and the most adequate punishment. Thus, in cases of suspected acquired pedophilia, a transdisciplinary and neuroscientific evaluation, including MRI, should be performed (Scarpazza, Ferracuti et al. 2018).

## 2. Etiology

The first important difference between idiopathic and acquired pedophilia lies in etiology: while idiopathic pedophilia is categorized within psychiatric disorders, acquired pedophilia clearly has a neurological origin. Idiopathic pedophilic disorder is considered to be a psychiatric disorder included within the paraphilias in the DSM 5 (Beech, Miner, & Thornton, 2016). It is present throughout the individual's life and it does not have a clear etiology. For this reason, idiopathic pedophilia is also called developmental pedophilia, to identify the form of pedophilic behavior that is present throughout the individual's life. Hereafter, we will refer to developmental pedophilia. Diagnostic criteria are still highly controversial. DSM-V to diagnose a paraphilia requires an “intense and persistent sexual interest other than sexual interest genital stimulation or preparatory fondling with phenotypically normal, physically mature, consenting human partners”. The condition must cause distress to the individual “whose satisfaction has entailed personal harm, or risk to harm to others” (DSM-V pag. 685-686). Offenders usually denies the sexual interest and the DSM-V states that when there is “substantial objective evidence to the contrary” (DSM-V p 696) the diagnosis can also be made. For paedophilia the DSMV requires sexually arousing fantasies or urges or behavior, involving sexual activity with a child of (mostly) 13 years or younger for a period of at least 6 months. The age of the victims should be at least 16 years and minimum 5 years older than the child. This condition is present since young adulthood, and different psychological and environmental theories have been proposed (Doshi, Zanzrukiya & Kumar 2018; Temberger et al. 2015).

Contrarily, acquired pedophilic behavior refers to a sexual urge toward children that emerges later in life as a consequence of an acquired neurological condition with clear neurologic etiology. Cases of pedophilia associated with brain damage have been described in patients with fron-

totemporal dementia (Mendez, 2010), brain tumor (Burns & Swerdlow, 2003), clivus chordoma (Sartori et al., 2016), surgical lesions (Devinsky, Sacks, & Devinsky, 2010), hippocampal sclerosis (Mendez & Shapira, 2011), multiple sclerosis (Frohman et al. 2002). These neurological insults seem to produce a “*behavioral fracture*” in the overt behavior manifested prior and after the brain disease insurgence (Scarpazza, Pellegrini, et al., 2018; Scarpazza, Pennati, & Sartori, 2018). To further discuss the causal role of neurological disorders on the insurgence of pedophilic behaviors, two cases are of particular relevance (Sartori et al. 2016; Burns & Swerdlow, 2003). In both cases, pedophilia emerged as a symptom of a tumor: a *clivus chordoma* (a slow growing tumor of the notochord, in this case displacing the hypothalamus and compressing the orbitofrontal cortex, (Sartori et al., 2016) and an hemangiopericytoma in the right orbitofrontal cortex (Burns & Swerdlow, 2003). In both cases, a *restitutio and integrum* of the symptomatology, including pedophilic urges, was documented after the surgical resection of the tumor, decreasing the causal link between the brain tumor and the pedophilic urges. In both cases, the tumor regrowth was accompanied by a re-insurgence of pedophilic interest, and a second surgical resection resulted again in a disappearance of the symptoms.

### 3. Neural correlates

The second important difference between developmental and acquired pedophilic behavior lies in their neural correlates. While developmental pedophilia is associated with subtle structural and /or functional abnormalities, acquired pedophiles clearly showed some evident neuroanatomical alteration.

According with its psychiatric etiology, developmental pedophilia is characterized by brain functional alterations or subtle structural alteration without evident neuroanatomical abnormalities (as for instance, brain tumor or lesions) (Mohnke et al., 2014). Indeed, psychiatric disorders have long been considered “functional” disorders, without a significant neural substrate. Despite in the last two decades neuroimaging research revealed that, using sophisticated statistical analysis on neuroimaging data, it is possible to observe neuroanatomical abnormalities in psychiatric disorders as well, literature has so far failed in identifying a consistent neuroanatomical substrate for psychiatric disorder, whom are still devoid of reliable biomarkers. This is true for pedophilia as well: quantitative voxel-based morphometric studies that demonstrated volume reductions of the right amygdala, hypothalamus, and septal regions (Poeppl et al., 2013; Schiltz et al., 2007), structural deficits of temporal cortices and fiber bundles (Cantor et al., 2008; Schiffer et al., 2007), and morphologic abnormalities of orbitofrontal cortex and basal ganglia (Schiffer et al., 2007). Further alterations appeared in areas in the parietal lobe (Cantor et al., 2008; Schiffer et al., 2007) as well as the cingulate cortex, insula, and cerebellum (Schiffer et al., 2007), when comparing pedophilic with nonpedophilic men. These alterations, which show a considerable variability be-

tween studies, seem to be congenital or to emerge very early during life, encompassing brain regions involved in sexual arousal (Tenbergen et al., 2015), such as the amygdala and the hypothalamus. The functional and structural brain alteration in developmental pedophilia are excellently summarized in two recent reviews (Mohnke et al. 2014; Tenbergen et al. 2015). Two critical points are worth noting: first, the inconsistent results available in the literature are the results of statistical analysis comparing a group of pedophiles versus a group of non pedophiles men. It is still not known whether the group level results can be useful to make inferences at the level of the single individual. Scientific research is still investigating this topic (Scarpazza et al., 2016; Vieira et al., 2019; Lui et al., 2019) and it is thus still not known the clinical implication of the group level results. Second, as pedophilia has high comorbidity with psychiatric disorders (Eher, Rettemberger & Turner, 2019), it is not possible to disentangle whether the results obtained so far truly reflect subtle neuroanatomical alterations of developmental pedophiles or whether these results are more likely to reflect structural alterations of the comorbid psychiatric disorders.

On the contrary, evident structural brain alterations emerging later in life are pivotal for the diagnosis of acquired pedophilic behavior. In acquired pedophilia, neuroanatomical alterations are clearly available in each individual patient, thus inferences can be made for each patient. Crucially, these alterations are in causal link with the insurgence of pedophilic urges. The neural network involved in the onset of this pathological behavior is still not fully understood, as it includes the right orbitofrontal cortex (Burns & Swerdlow, 2003; Fumagalli, Pravettoni, & Priori, 2015), the right amygdala (Devinsky et al., 2010), the right globus pallidus (Mendez & Shapira, 2011) the hypothalamus (Frohman, Frohman, & Moreault, 2002; Miller et al., 1986; Sartori et al., 2016), the hippocampus bilaterally (Mendez & Shapira, 2011; Mendez, 2010; Mendez et al., 2000), the basal ganglia bilaterally (Mendez & Shapira, 2011). These regions seem to be associated with a network involved in diminished behavioral control (Mohnke et al., 2014).

### 4. Which reliable neural basis in acquired pedophilic behavior?

As described in the previous paragraph, the brain insults leading to pedophilic behavior onset were spatially heterogeneous, including the frontal cortex, the putamen, the hippocampus, for instance. As each region impaired by the brain insult is part of a network of brain regions working in synergy, we tried to identify the neural network consistently impaired across patients with acquired pedophilic behavior. In a preliminary study, brain lesions of patients with acquired pedophilic behavior identified in the literature ( $n = 10$ ) were manually delineated and were used as individual seeds in a resting-state connectivity analysis using data from 20 healthy subjects. Functional connectivity to each lesion

was determined by calculating the correlated time course between each lesion location and every other brain voxel using the resting-state data from each individual normal control. These correlations for all 20 subjects were then combined to calculate a T-score value for each voxel. Finally, maps from all patients were combined to create a conjunction analysis that identifies the network involved in

every patient with acquired pedophilia (Darby et al. 2017).

The results of this preliminary analysis revealed that all brain lesions in individuals with acquired pedophilia were functionally connected to the orbitofrontal cortex (See Figure 1). These brain regions are known to be involved in impulse inhibition and in the neurophenomenological model of sexual arousal (Stoleru et al. 2012).

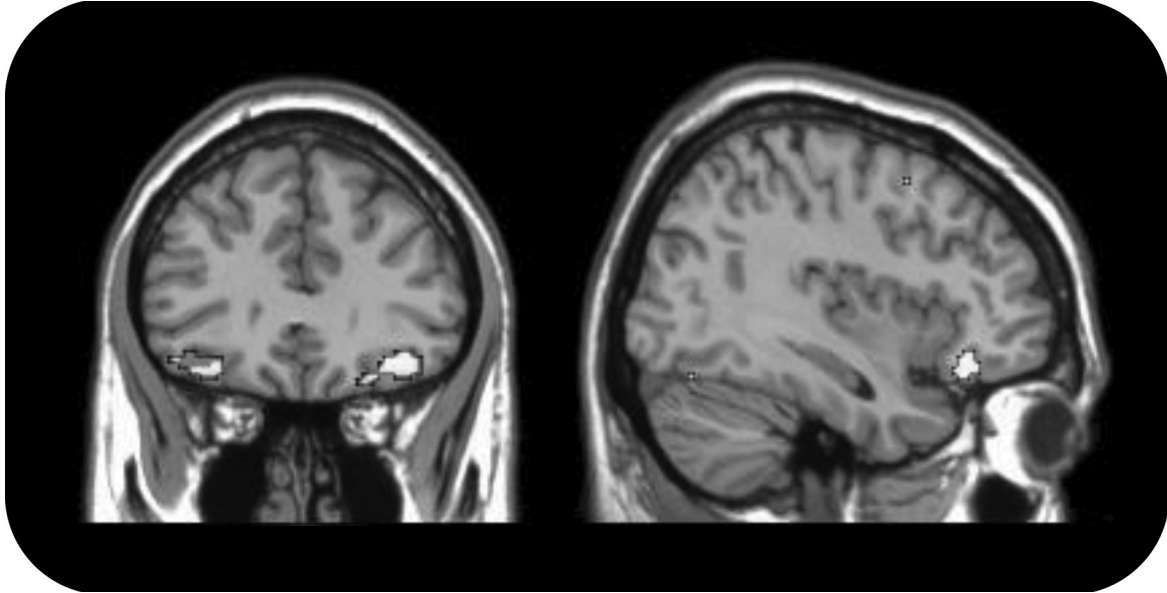


Figure 1. Results of the analyses we conducted revealing the brain regions consistently involved in acquired pedophilia.

## 5. Modus Operandi

The third important difference between developmental and acquired pedophiles lies in their *modus operandi*. While the *modus operandi* of developmental pedophiles has been described as predatory, the one of acquired pedophilia is usually impulsive.

Developmental pedophiles are described to actively search for victims, organize their action, mask their sexually abusing behavior, enforcing victim's silence, using psychological and physical violence (Hall & Hall, 2007; Miranda & Corcoran, 2000) and, if caught, might deny their behavior (Fagan et al. 2002; Hall & Hall, 2007). The first studies which specifically analyzed the *modus operandi* of sexual offenders against children were conducted in the late 1980s. These studies clarified that offender has to choose his hunting ground, that is, the places where he is likely to encounter a potential victim and the time when he is going to offend. Following these decisions, the offender has to select a victim according to his/her erotic value (age, gender and physical characteristics), to his/her vulnerability (physical and/or psychological) and to his/her familiarity. Finally, the offender has to decide how he is going to approach the victim and which strategy he will adopt to get the victim involved in sexual activity. These early studies provided crucial data to understand the strategies adopted by sexual offenders against children to commit their crimes. For instance, offenders have been found to gradually desensitize

the victim to physical contact before moving to sexual touch (Berliner & Conte, 1990; Christiansen and Blake, 1990). Offenders also use some type of coercion and threats (Berliner & Conte, 1990; Budin & Johnson, 1989). Using a sample of 226 adult offenders, Leclerc, Carpentier & Proulx (2006) studied the impact of several factors, such as the age of the victim (0–13 years old), on the likelihood of adopting a manipulative, a coercive or a non-persuasive strategy to involve the victim in sexual activity. They found that adult offenders who sexually abuse older children were more likely to use a manipulative, rather than a non-persuasive strategy. Thus, developmental pedophiles offenses are planned in detail.

Contrarily, individuals with acquired pedophilia usually lack of premeditation (Gilbert & Focquaert, 2015; Sartori et al., 2016) and do not attempt to disguise their criminal behavior (Burns & Swerdlow, 2003; Mendez & Shapira, 2011; Sartori et al., 2016; Scarpazza, Pellegrini, et al., 2018; Scarpazza, Pennati, & Sartori, 2018). The selection of the victims is not thoughtful as a result of the absence of premeditation. For instance, one patient described in the literature abused his own daughter (Raniero et al., 2011), another one abused his own step daughter (Gilbert & Vranic 2015), another one was a pediatrician and abused his patients in front of the parents (Sartori et al., 2016), another one masturbated in front of a school that was just outside his home (Scarpazza et al., 2018). These latter behavior can also be observed in dementia patient or in per-

sons with severe intellectual disability. In other words, they victimized children even if the likelihood to be discovered is very high. These probably reflect the impulse discontrol that characterize patients with acquired pedophilia (Mohnke et al., 2014) and it might be considered in anatomo clinical correlation with the consistent neural basis identified in the previous paragraph.

## 6. Possible treatments

The fourth important difference between developmental and acquired pedophilia lies in the possible treatment. While developmental pedophilia is the primary condition that needs to be treated, acquired pedophilia can theoretically be treated by treating the underlying neurological condition.

There seems to be no evidence to suggest that developmental pedophilia can be changed and no treatment is effective unless the pedophile is willing to engage in the treatment (Hall & Hall, 2007, Stone et al., 2000). Instead, psychotherapeutic interventions are designed to increase voluntary control over sexual arousal, reduce sex drive, or teach self-management skills to individuals who are motivated to avoid acting upon their sexual interests (Seto, 2009). Despite psychotherapy is an important aspect of treatment, debate exists concerning its overall effectiveness for a long-term prevention of new offenses (Hanson et al. 2005, Langton et al. 2006, Hall & Hall, 2007). For this reason, psychotherapy is often coupled with androgen deprivation therapy (ADT), by which the individual's testosterone level is lowered to a pre-pubescent level, thereby eliminating or severely reducing sexual urges (Thibaut et al., 2010), or with the administration of selective serotonin reuptake inhibitors, that represent a non-hormonal treatment that has been suggested for paraphilias in general and for specifically for pedophilia (Stone et al. 2000, Hall & Hall, 2007). Interestingly, after a year of combined psychotherapy and pharmacotherapy, pedophiles individuals still show sexual interest for children, whereas their frequency of urges decrease (Schober et al., 2005), indicating that, while urges can be managed, the core attraction for children does not change (Schober et al., 2005; Hall & Hall, 2007). Critically, offenders commonly do not comply with psychological and medical treatments (Fagan 2002; Stone et al., 2000) being at high risk of sexual recidivism (Seto et al., 2004; Seto, 2009; Hanson et al., 2003; Hanson & Morton-Bourgon, 2005).

Contrarily, acquired pedophilia can theoretically be addressed by treating the underlying medical condition (Sartori et al., 2016). For instance, pedophilia can recede after surgical resection of the tumor causing it (Burns & Swerdlow, 2003; Sartori et al., 2016; Gilbert & Vranic, 2015). So far, no sexual recidivism has been described in individuals free from the neurological disorder causing pedophilia, being pedophilic urges only recurrent only when the neurological disorder itself re-occur, as explained in the paragraph on etiological origin.

## 7. Legal Consequences

The four important differences described in the previous paragraphs, namely etiology, neural basis, *modus operandi* and treatments, could potentially have a decisive impact on offenders' judicial consequences.

The legal consequences for developmental pedophiles are always severe and insanity is not commonly considered. Indeed, according with the *actio libera in causa* principle, developmental pedophiles, who are aware of their abnormal urges and of the moral and legal disvalue of their potential behavior and who are cognitively intact, should not put themselves in the condition being in the same place with children. Their planned and strategic behavior is instead an indication of their voluntary decision to hunt children.

On the contrary, insanity is a relevant matter for acquired pedophiles. Indeed, both the ability to understand the moral and social value of one's own action and the ability to exert control over impulses are pivotal to the capacity for self-determination. As individual with acquired pedophilia usually lack of these abilities, insanity becomes a relevant and controversial issue in these cases (Gilbert & Focquaert, 2015). For these reasons, individuals with acquired pedophilia might be considered not fully liable for their pedophilic behavior (Burns & Swerdlow, 2003; Devinsky et al., 2010; Gilbert, 2013; Gilbert & Vranic, 2015; Gilbert et al., 2016; Scarpazza, Pennati et al., 2018). However, only few cases, summarized in Table 1, are available in the literature and the legal consequences are rarely reported. The identification of a neurological disorder in a defendant charged with pedophilia could be *per se* sufficient to claim his lack of accountability. Whether or not an offender manifesting acquired pedophilic behavior should be held responsible needs to be delicately assessed on a case by case basis (Gilbert, 2013; Gilbert & Focquaert, 2015).

Author's&date	Country	Aetiology	Moral Judgement	Impulse discontrol	Legal consequences
von Krafft-Ebing, 1897	France	Dementia	Impaired	Not clear	Not Responsible
Lesniak et al. 1972	Poland	Tumor in the right frontal lobe	Impaired	Impaired	n/a
Regestein et al. 1978	n/a	Meningioma involving the right frontal lobe	n/a	n/a	n/a
Miller et al. 1986	USA	Tumor in the brainstem and hypothalamus	Impaired	Impaired	n/a
Mendez et al. 2000, case 1	California	bvFTD	Impaired	Impaired	n/a
Mendez et al. 2000, case 2	California	Bilateral hippocampal sclerosis	n/a	n/a	Responsible
Frohman et al. 2002	USA	Multiple Sclerosis (hypothalamic lesion)	Preserved	Impaired	Responsible
Burns & Swerdlow 2003	USA	OFC neoplasm	Preserved	Impaired	Not responsible
Solla et al. 2006	Italy	HHD in PD	Preserved	Impaired	Not applicable
Prahlada Rao et al. 2007	India	unknown	Preserved	n/a	Not applicable
Devinsky et al. 2009	USA	Gangoglioma that caused a kuver-bucy syndrome	Preserved	Impaired	Partially responsible (26 months)
Mendez and Shapira, 2011, case 2	USA	bvFTD	Impaired	Impaired	n/a
Menzed and Shapira, 2011, case 3	USA	Frontal variant AD	n/a	n/a	n/a
Menzed and Shapira, 2011, case 4	USA	Globus pallidus lacune	n/a	Impaired	n/a
Menzed and Shapira, 2011, case 5	USA	PD	Preserved	Impaired	Imprisoned (not clear whether insanity was considered)
Menzed and Shapira, 2011, case 6	USA	Hungtington's disease	Impaired	Impaired	n/a
Menzed and Shapira, 2011, case 7	USA	Pallidotomy for PD	Preserved	Impaired	n/a
Raniero et al. 2011	Italy	Genetic FTD	Impaired	Impaired	Not applicable
Fumagalli et al. 2014	Italy	Frontal lobe Brain Injury	Not clear	Impaired	n/a
Gilbert & Vranic 2015; Gilbert et al. 2016	Slovenia	Tumor (glioblastoma multiforme) in the left frontal lobe	n/a	n/a	Pending
Alnemari et al. 2016	United stated	temporal and frontal encephalo- malacia	n/a	n/a	n/a
Sartori et al. 2016; Scarpazza et al. 2018	Italy	Clivus Chordoma	Impaired	Impaired	Responsible
Scarpazza et al. 2018, case 1	Italy	bvFTD	Impaired	Impaired	n/a
Scarpazza et al. 2018, case 1	Italy	Fronto-parietal meningioma	n/a	Impaired	n/a

TABLE 1. Cases of acquired pedophilia in the literature

Abbreviations: AD: Alzheimer's disease; HHD: Hedonistic homeostatic dysregulation (neuropsychiatric complication described in patients with Parkinson's disease, characterized by misuse of and addiction to dopaminergic drugs); PD: Parkinson's disorder; OFC: Orbitofrontal Cortex; bvFTD: Behavioral variant of fronto-temporal dementia; n/a: Information not available (not reported in the paper); not applicable: the patient never acted his pedophilic urges.

## 8. Conclusion

Appreciating the possibility of an acquired cause of pedophilic behavior is of utmost importance, for clinical and forensic reasons. (Scarpazza, Pennati, et al., 2018). An interdisciplinary approach must be acted in all cases under observation (Burns & Swerdlow, 2003; Rainero et al., 2011; Sartori et al., 2016). The identification of a neurological condition gives opportunity to treatment that otherwise would be denied. Furthermore the forensic evaluation of a person with a neurological condition correlated with pedophilic behavior cannot be the same of a person with developmental pedophilia. In the latter case the behavior is expression of an ego-syntonic desire, were the antisocial component is clearly understood, and a degree on control of voluntary behavior can be acted, as usually demonstrated by victim selection and modus operandi. In acquired pedophilia the person develops urges and behavior that are not congruent with the previous personal sexual history and often does not have a clear understanding of the situation. In these acquired cases a strong consideration of insanity defense can be considered by the expert evaluation.

## References

Alnemari, A. M., Mansour, T. R., Buehler, M., & Gaudin, D. (2016). Neural basis of pedophilia: Altered sexual preference following traumatic brain injury. *Int J Surg Case Rep*, 25, 221-224. doi:10.1016/j.ijscr.2016.06.035

Beech, A. R., Miner, M. H., & Thornton, D. (2016). Paraphilias in the DSM-5. *Annu Rev Clin Psychol*, 12, 383-406. doi:10.1146/annurev-clinpsy-021815-093330

Berliner, L. and Conte, J. R. (1990). The process of victimization: The victim's perspective. *Child Abuse and Neglect*, 14, 29-40.

Budin, L. E. and Johnson, C. F. (1989). Sex abuse prevention programs: Offenders' attitudes about their efficacy. *Child Abuse and Neglect*, 13, 77-87.

Butler, C., & Zeman, A. Z. (2005). Neurological syndromes which can be mistaken for psychiatric conditions. *J Neurol Neurosurg Psychiatry*, 76 Suppl 1, i31-38. doi:10.1136/jnnp.2004.060459

Burns, J. M., & Swerdlow, R. H. (2003). Right orbitofrontal tumor with pedophilia symptom and constructional apraxia sign. *Arch Neurol*, 60(3), 437-440.

Cantor, J.M., Kabani, N., Christensen, B.K., Zipursky, R.B., Barbaree, H.E., Dickey, R., Klassen, P.E., Mikulis, D.J., Kuban, M.E., Blak, T., Richards, B.A., Hanratty, M.K., Blanchard, R. (2008). Cerebral white matter deficiencies in pedophilic men. *J Psychiatr Res.*, 42, 167-83.

Christiansen, J. R. and Blake, R. H. (1990). The grooming process in father-daughter incest. In A. L. Horton, B. L. Johnson, L. M. Rowndy and D. Williams (Eds.), *The incest perpetrator: A family member no one wants to treat* (pp. 88-98). Sage Publications.

Darby, R. R., Horn, A., Cushman, F., Fox, M.D. (2018). Lesion network localization of criminal behavior. *PNAS*, 115(3), 601-606.

Devinsky, J., Sacks, O., & Devinsky, O. (2010). Klüver-Bucy syndrome, hypersexuality, and the law. *Neurocase*, 16(2), 140-145. doi:10.1080/13554790903329182

Doshi SM., Zanzrukiya K., Kumar L. (2018). Paraphilic infantil-

ism, diaperism and pedophilia: A review. *Journal of Forensic and Legal Medicine*, 56, 12-15.

Eher, R., Rettemberger, M. & Turner D. (2019). The prevalence of mental disorders in incarcerated contact sexual offenders. *Acta Psychiatr Scand*. Jun, 139(6), 572-581. doi: 10.1111/acps.13024. Epub 2019 Apr 9.

Fagan, P. J., Wise, T. N., Schmidt, C. W., Jr., & Berlin, F. S. (2002). Pedophilia. *JAMA*, 288(19), 2458-2465. doi:10.1001/jama.288.19.2458

Frohman, E. M., Frohman, T. C., & Moreault, A. M. (2002). Acquired sexual paraphilia in patients with multiple sclerosis. *Arch Neurol*, 59(6), 1006-1010.

Fumagalli, M., Pravettoni, G., & Priori, A. (2015). Pedophilia 30 years after a traumatic brain injury. *Neurol Sci*, 36(3), 481-482. doi:10.1007/s10072-014-1915-1

Gilbert, F. (2013). Does neuropathology dictate morality? Acquired paedophilia as a neuroethical case. In *Morality: Reasoning on Different Approaches*, Vasil Gluchman (ed.), Rodopi Publication. Value Inquiry Book Serie. Amsterdam New-York, 97-110.

Gilbert, F., & Focquaert, F. (2015). Rethinking responsibility in offenders with acquired paedophilia: punishment or treatment? *Int J Law Psychiatry*, 38, 51-60. doi:10.1016/j.ijlp.2015.01.007

Gilbert, F., & Vranic, A. (2015). Paedophilia, Invasive Brain Surgery, and Punishment. *J Bioeth Inq*, 12(3), 521-526. doi:10.1007/s11673-015-9647-3

Gilbert, F., Vranic, A., & Viaña, J. M. N. (2016). Acquired Pedophilia and Moral Responsibility. *AJOB Neuroscience*, 7(4), 209-211.

Hall, R. C., & Hall, R. C. (2007). A profile of pedophilia: definition, characteristics of offenders, recidivism, treatment outcomes, and forensic issues. *Mayo Clin Proc*, 82(4), 457-471. doi:10.4065/82.4.457

Hanson, R.K., Morton, K.E., Harris, A.J. (2003) Sexual offender recidivism risk: what we know and what we need to know. *Ann N Y Acad Sci*, 989, 154-166.

Hanson, R. K., & Morton-Bourgon, K. E. (2005). The characteristics of persistent sexual offenders: a meta-analysis of recidivism studies. *J Consult Clin Psychol*, 73(6), 1154-1163. doi:10.1037/0022-006X.73.6.1154

Keshavan, M. S., & Kaneko, Y. (2013). Secondary psychoses: an update. *World Psychiatry*, 12(1), 4-15. doi:10.1002/wps.20001

Langton, C.M., Barbaree, H.E., Harkins, L., Peacock, E.J. (2006) Sex offenders' response to treatment and its association with recidivism as a function of psychopathy. *Sex Abuse*, 18, 99-120.

Leclerc, B., Proulx, J. and McKibben, A. (2005). Modus operandi of sexual offenders working or doing voluntary work with children and adolescents. *Journal of Sexual Aggression*, 2, 187-195.

Lei, D., Pinaya, W.H.L., van Amelswoort, T., Marcelis, M., Donohoe, G., (...) Scarpazza, C., & Young, J. et al. (2019). Detecting schizophrenia at the level of the individual: relative diagnostic value of regional activation, connectome-wide functional connectivity and graph-based networks. *Psychological Medicine*. In press.

Lesniak, R., Szymusik, A., & Chrzanowski, R. (1972). Case report: Multidirectional disorders of sexual drive in a case of brain tumour. *Forensic Sci*, 1(3), 333-338.

Mendez, M. F., Chow, T., Ringman, J., Twitchell, G., & Hinkin, C. H. (2000). Pedophilia and temporal lobe disturbances. *J Neuropsychiatry Clin Neurosci*, 12(1), 71-76. doi:10.1176/jnp.12.1.71

Mendez, M. F. (2010). The unique predisposition to criminal violations in frontotemporal dementia. *J Am Acad Psychiatry Law*, 38(3), 318-323.

Mendez, M., & Shapira, J. S. (2011). Pedophilic behavior from brain disease. *J Sex Med*, 8(4), 1092-1100. doi:10.1111/j.1743-6109.2010.02172.x

- Miller, B. L., Cummings, J. L., McIntyre, H., Ebers, G., & Grode, M. (1986). Hypersexuality or altered sexual preference following brain injury. *J Neurol Neurosurg Psychiatry*, 49(8), 867-873. doi:10.1136/jnnp.49.8.867
- Miranda, A. O., & Corcoran, C. L. (2000). Comparison of penetration characteristics between male juvenile and adult sexual offenders: preliminary results. *Sex Abuse*, 12(3), 179-188. doi:10.1177/107906320001200302
- Mohnke, S., Müller, S., Amelung, T., Kruger, T. H., Ponseti, J., Schiffer, B., . . . Walter, H. (2014). Brain alterations in paedophilia: a critical review. *Prog Neurobiol*, 122, 1-23. doi:10.1016/j.pneurobio.2014.07.005
- Poepl, T.B., Nitschke, J., Santtila, P., Schecklmann, M., Langguth, B., Greenlee, M.W., Osterheider, M., Mokros, A. (2013). Association between brain structure and phenotypic characteristics in pedophilia. *J Psychiatr Res*. 47:678-85.
- Prahlada Rao, N., Chand, P.K., Murthy, P. (2007). A Case of Late-Onset Pedophilia and Response to Sertraline. *Prim Care Companion J Clin Psychiatry*, 9(3).
- Rainero, I., Rubino, E., Negro, E., Gallone, S., Galimberti, D., Gentile, S., . . . Pinessi, L. (2011). Heterosexual pedophilia in a frontotemporal dementia patient with a mutation in the progranulin gene. *Biol Psychiatry*, 70(9), e43-44. doi:10.1016/j.biopsych.2011.06.015
- Regestein, Q. R., & Reich, P. (1978). Pedophilia occurring after onset of cognitive impairment. *J Nerv Ment Dis*, 166(11), 794-798.
- Sartori, G., Scarpazza, C., Codognotto, S., & Pietrini, P. (2016). An unusual case of acquired pedophilic behavior following compression of orbitofrontal cortex and hypothalamus by a Clivus Chordoma. *J Neurol*, 263(7), 1454-1455. doi:10.1007/s00415-016-8143-y
- Scarpazza, C., Ferracuti, S., Miolla, A., Sartori, G. (2018). The charm of structural neuroimaging in insanity evaluation: guidelines to avoid misinterpretation of the findings. *Translational Psychiatry*, 8(1), 227.
- Scarpazza, C., Nichols, T.E., Seramondi, D., Maumet, C., Sartori, G., Mechelli, A. (2016). When the single matter more than group (II): addressing the problem of high false positive rates in single case Voxel Based Morphometry using non-parametric statistics. *Frontiers in Neuroscience, section Brain Imaging Methods*. 10:6.
- Scarpazza, C., Pellegrini, S., Pietrini, P., & Sartori, G. (2018). The role of Neuroscience in the Evaluation of Mental Insanity: on the controversies in Italy. *Neuroethics*, 11(1), 83-95.
- Scarpazza, C., Pennati, A., & Sartori, G. (2018). Mental Insanity Assessment of Pedophilia: The Importance of the Trans-Disciplinary Approach. Reflections on Two Cases. *Front Neurosci*, 12, 335. doi:10.3389/fnins.2018.00335
- Schiltz, K., Witzel, J., Northoff, G., Zierhut, K., Gubka, U., Fellmann, H., Kaufmann, J., Tempelmann, C., Wiebking, C., Bogerts, B. (2007). Brain pathology in pedophilic offenders: evidence of volume reduction in the right amygdala and related diencephalic structures. *Arch Gen Psychiatry*. 2007; 64, 737-46.
- Schiffer, B., Peschel, T., Paul, T., Gizewski, E., Forsting, M., Leygraf, N., Schedlowski, M., Krueger, T.H.C. (2007). Structural brain abnormalities in the frontostriatal system and cerebellum in pedophilia. *J Psychiatr Res*. 41, 753-62.
- Schober, J.M., Kuhn, P.J., Kovacs, P.G., Earle, J.H., Byrne, P.M., Fries, R.A. (2005). Leuprolide acetate suppresses pedophilic urges and arousability. *Arch Sex Behav.*, 34, 691-705.
- Seto, M.C., Harris, G.T., Rice, M.E., Barbaree, H.E. (2004) The screening scale for pedophilic interests predicts recidivism among adult sex offenders with child victims. *Arch Sex Behav*. 33:455-466.
- Seto, M. C. (2009). Pedophilia. *Annu Rev Clin Psychol*, 5, 391-407. doi:10.1146/annurev.clinpsy.032408.153618
- Solla, P., Floris, G., Tacconi, P., & Cannas, A. (2006). Paraphilic behaviours in a parkinsonian patient with hedonistic homeostatic dysregulation. *Int J Neuropsychopharmacol*, 9(6), 767-768. doi:10.1017/S1461145705006437
- Stone, T. H., Winslade, W. J., & Klugman, C. M. (2000). Sex offenders, sentencing laws and pharmaceutical treatment: a prescription for failure. *Behav Sci Law*, 18(1), 83-110.
- Thibaut, F., De La Barra, F., Gordon, H., Cosyns, P., Bradford, J.M.W., & Disorders, W.T.F., et al. (2010). The World Federation of Societies of Biological Psychiatry (WFSBP). Guidelines for the biological treatment of paraphilias. *World Journal of Biological Psychiatry*, 11(4), 604-655.
- Tenbergen, G., Wittfoth, M., Fieling, H., Ponseti, J., Walter, M., Walter, H., . . . Kruger, T. H. (2015). The Neurobiology and Psychology of Pedophilia: Recent Advances and Challenges. *Front Hum Neurosci*, 9, 344. doi:10.3389/fnhum.2015.00344
- Vieira, S., Gong, Q., Pinaya, W.H.L., Scarpazza, C., Tognin, S. (...) McGuire, P., Mechelli, A. (2019). Using machine learning and structural neuroimaging to detect first episode psychosis: re-considering the evidence. *Schizophrenia Bulletin*. In Press.
- von Krafft-Ebing, B. (1897). *Trattato di psicopatologia forense*. Torino: Fratelli Bocca, 215.